

A field study on occurrence of vertebral deformities in Atlantic salmon (*Salmo salar* L.) from two rivers in Western Norway

Florian Sambraus¹, Kevin A. Glover², Tom Hansen¹, Monica Solberg², Thomas W. K. Fraser³, Per Gunnar Fjelldal¹

¹Institute of Marine Research (IMR), Matre Research Station, N-5984 Matredal, Norway; ²Institute of Marine Research (IMR), Bergen, Norway; ³Department of Production Animal Clinical Sciences, Norwegian School of Veterinary Science, Oslo, Norway

Introduction

To date there are no reports on the occurrence of vertebral deformities in wild Atlantic salmon. In Atlantic salmon aquaculture, deformities in the vertebral column are a common problem, causing down-grading losses and raising welfare concerns.

Material and methods

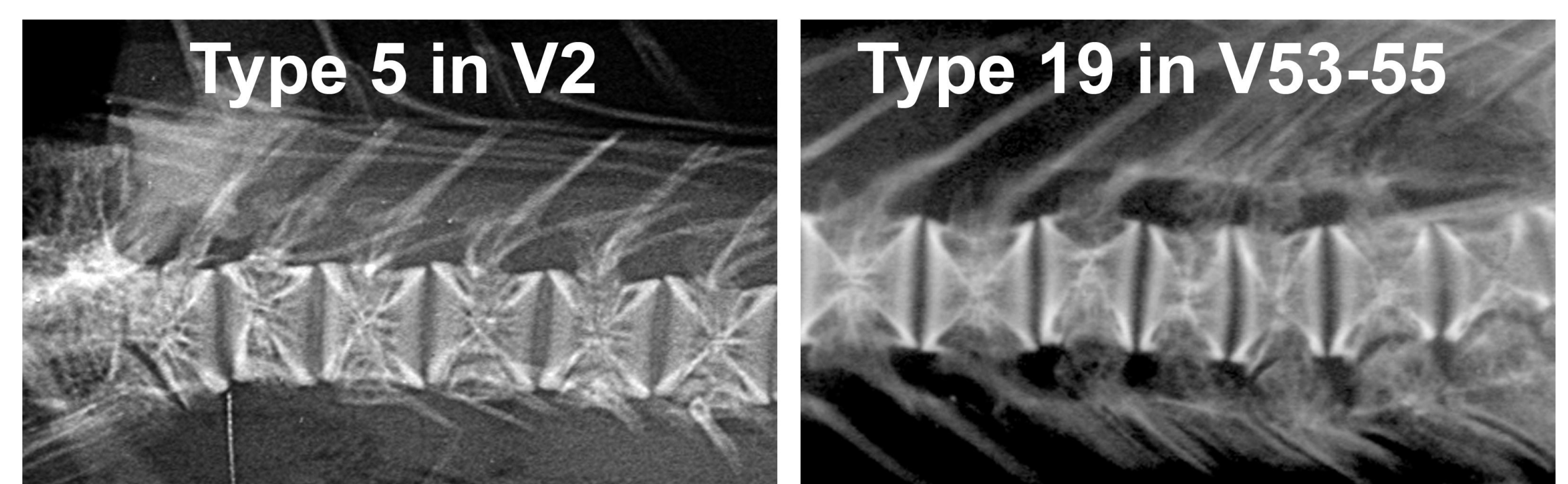
Wild adult river migrating Atlantic salmon, sampled from two rivers in Western Norway, Arna 2012 (n = 22) and Figgjo 2010 to 2012 (n = ~25/year), were x-rayed for vertebral deformities. Wild status and age was confirmed through scale analyses. The age of all sampled fish ranged from 3 to 5 years.

Results

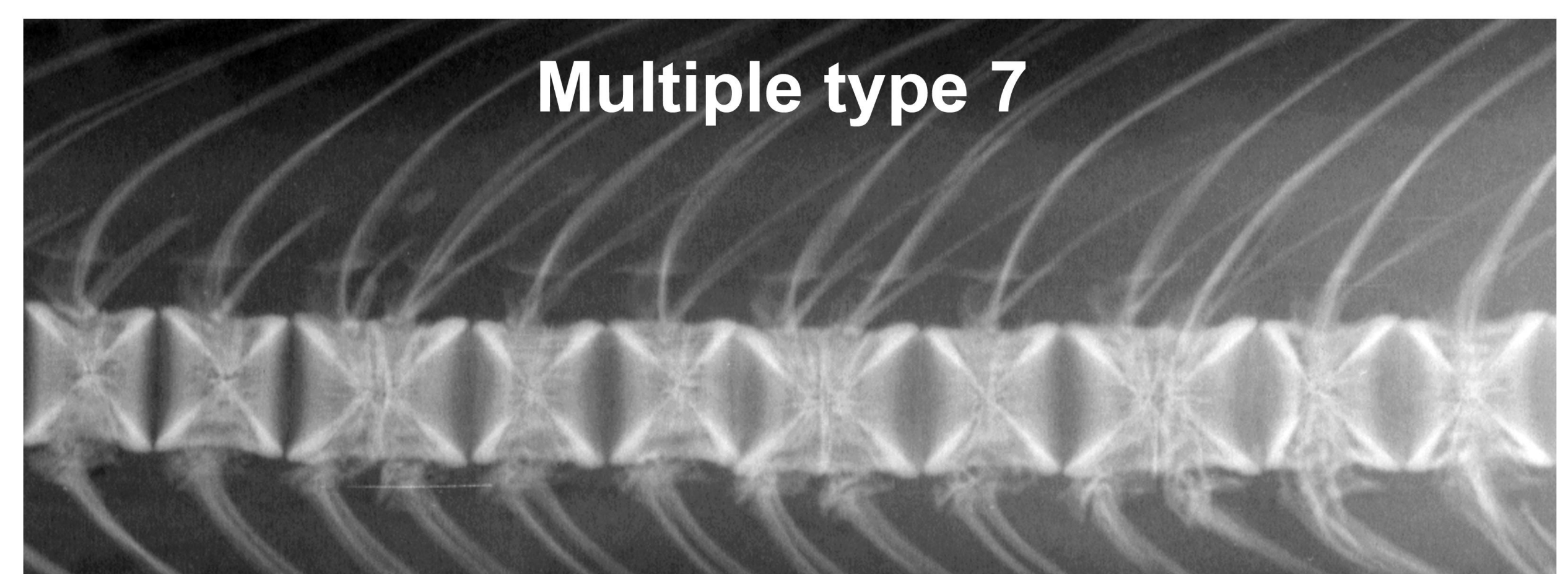
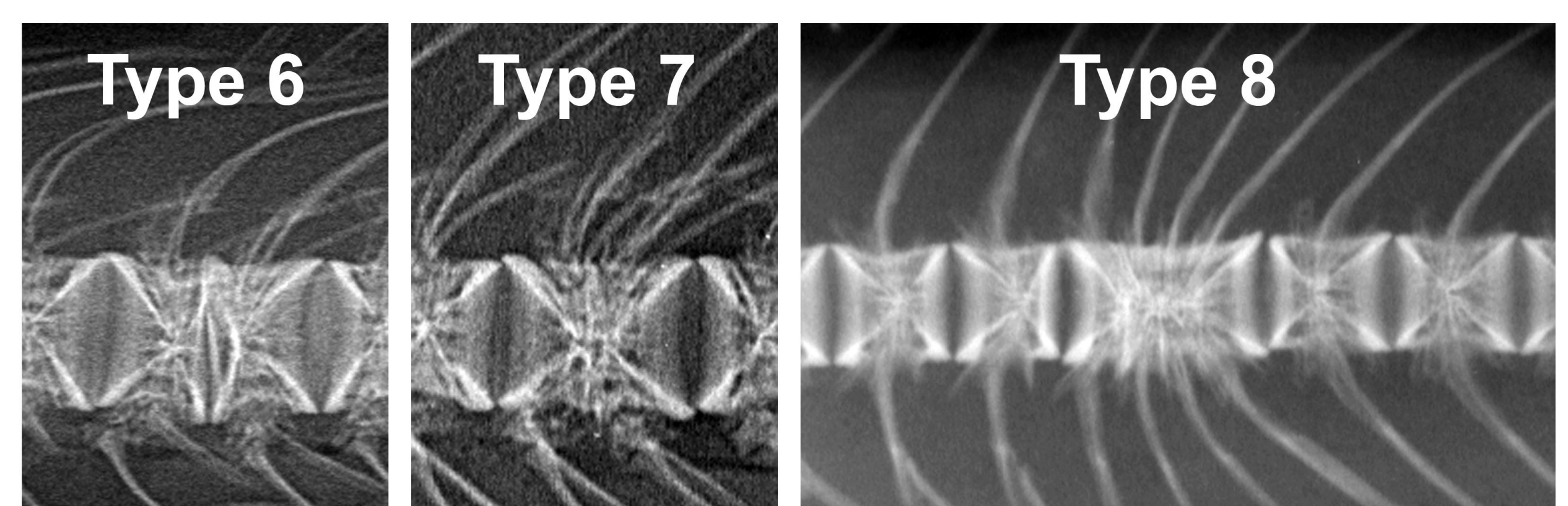
Minor deformities like one-sided compressions (type 5), and internal dorsal or ventral shifts (type 19) were repeatedly observed in all groups. Type 5, mostly found in vertebra (V) 2, and type 19 within V52-56. No other compression related deformities were detected. However, a clear trend towards a reduction in fusion related deformities (compression and fusion: type 6, complete fusion: type 7, and fusion centre: type 8) from 2010 to 2012 (2010: 29%, 2011: 17%, 2012: 5%) in Figgjo was observed. The most common type of fusion was type 7. No fusion related deformities were found in fish from river Arna. The occurrence of fish with one or more deformed vertebrae ranged between 33 and 50% in the analyzed groups.



Minor compressions



Fusions



Conclusions

- Compression related deformities found in wild salmon were neither severe, nor similar to compressions most often reported in adult farmed fish
- Fusion related deformities were only found in fish from river Figgjo. Here their occurrence significantly decreased from 2010 to 2012
- Fusions were mostly of type 7, indicating that wild salmon have a strong capability of 'repairing' vertebra pathologies

Acknowledgements

This study was supported by the Fiskeri- og havbruksnæringens forskningsfond (FHF) funded project 'Fosforbehov hos hurtigvoksende laks i ferskvann og tidligsjøfase for å sikre god benhelse' (project no. 900798).